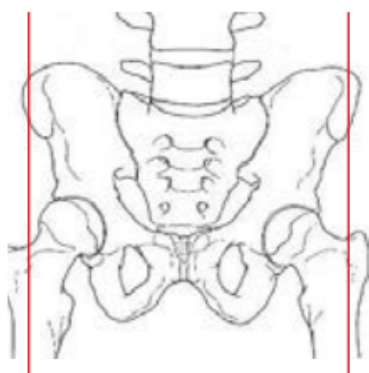

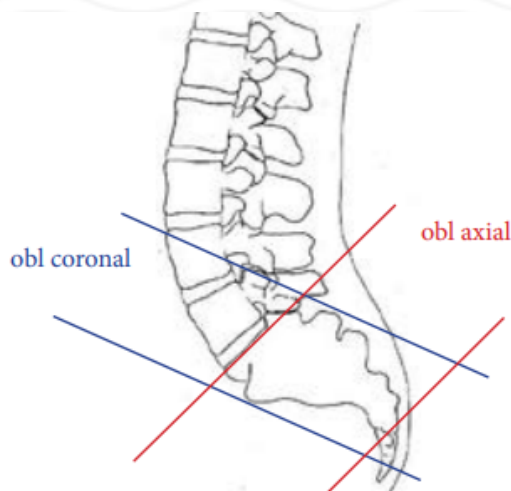
MRI LUMBAR SACRAL PLEXUS/ SACROILIITIS WITHOUT & WITH

Patient Position	Supine-include BOTH sides of sacrum
FOV	Fits to patient/ body part
Localizer	3 plane scout localizer
Scan Range	Dome of diaphragm through aortic bifurcation
Note	Arms out of FOV
	Abnormalities should be in one stack of axials.
	Do NOT place the end or beginning of the stack within the abnormality!

PLANE	SEQUENCE	FAT SAT	FOV	NOTES
Oblique axial	T1	Y	16-18 cm	
Oblique axial	Mod T2	Y		
Oblique coronal	T1			Oblique coronal angled parallel to upper sacral axis
Oblique coronal	T2	Y		Oblique coronal angled parallel to upper sacral axis
Sagittal	T2	Y		
Oblique axial + C	T1	Y		Perpendicular to oblique coronals (parallel to L5-S1 disc)
Oblique coronal + C	T1	Y		Oblique coronal angled parallel to upper sacral axis



sagittal



obl coronal

obl axial

Any deviation from protocol MUST be Radiologist approved. Rad Director will be notified if this occurs without prior approval.