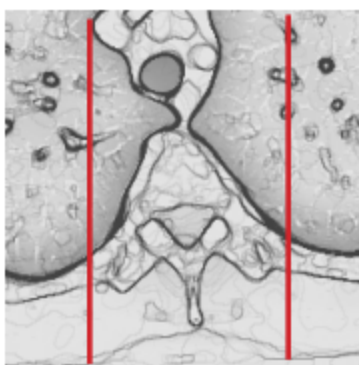
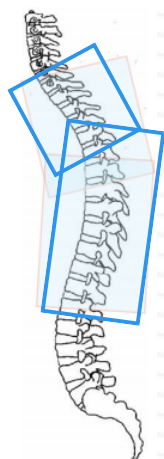


MRI T- SPINE WITHOUT & WITH CONTRAST

Indications	Myelopathy, cord disease, Syrinx, MS, infection, tumor, mets, discitis, intramedullary disease, complicated post-op problems, osteomyelitis
Localizer	3 plane scout
Note	Contrast for the thoracic spine will be used in special circumstances only. If there is a question about the appropriateness of GAD use, contact the Radiologist.
	Contact the Radiologist if the patient has multi-level spine studies ordered before performing any of the studies.

PLANE	SEQUENCE	FAT SAT	SLT/SP	FOV	NOTES
Sagittal counting	T2		3 / 1	50 cm	Must include C2 through T12 with NO scout pre-sat band so that levels can be accurately counted from above. If surgical artifact obscures cervical disc detail, add lumbar scout including L5-S1.
Sagittal	T1		3 / 1	30 cm	
Sagittal	STIR		3 / 1	30 cm	
Sagittal	T2		3 / 1	30 cm	
Axial	T1	Y	4 / 1	16 - 18 cm	C7 - L1 two stacks optional if needed
Axial	T2		4 / 1	16 - 18 cm	C7 - L1 two stacks optional if needed
Axial	3D T2		4 / 1	16 - 18 cm	C7 - L1 two stacks optional if needed
Axial + C	T1	Y	4 / 1	16 - 18 cm	C7 - L1 two stacks optional if needed
Sagittal + C	T1	Y	3 / 1	30 cm	



- Abnormalities should be in one stack of axials.
- Do not place the end or beginning of the stack within the abnormality!
- axial images are typically split into two stacks that should overlap
- The orientation of the two axial stacks should be perpendicular to as many discs as possible