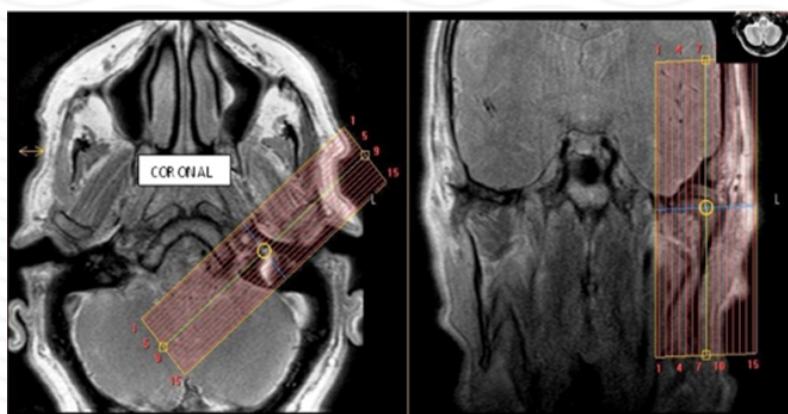


MRI TMJ Without contrast

| Indications | clicking, pain, decreased ROM |
|-------------|--|
| Notes | Always scan bilaterally. Scan right and left sides separately. LABEL sides correctly. |

| PLANE | SEQUENCE | FAT SAT | MODE | SLT/SP | FOV | NOTES |
|-------------------------|------------------|---------|------|--------|-------|--|
| Axial | T1 | | | 4/1 | 23 cm | Angle to Corpus - skull base to vertex |
| Sagittal (right & left) | PD closed | | TSE | 2/0 | 12 cm | Perpendicular to long axis |
| Sagittal (right & left) | T2 closed | | TSE | 2/0 | 12 cm | Perpendicular to long axis |
| Coronal (right & left) | T2 closed | | TSE | 2/0 | 12 cm | Parallel to long axis |
| Sagittal (right & left) | PD open | | TSE | 2/0 | 12 cm | Perpendicular to long axis |

Coronal



Sagittal

