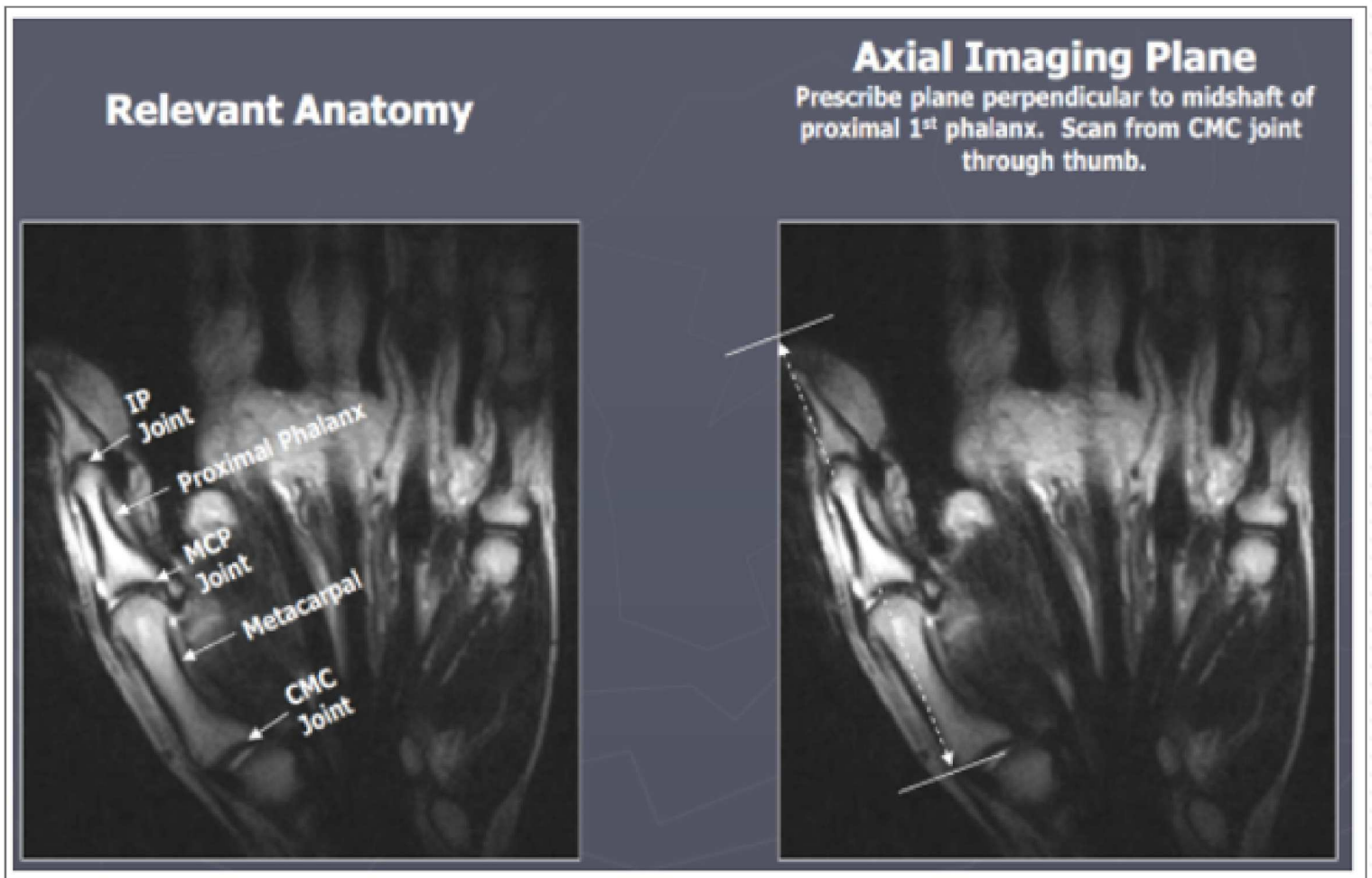


MRI Thumb without contrast

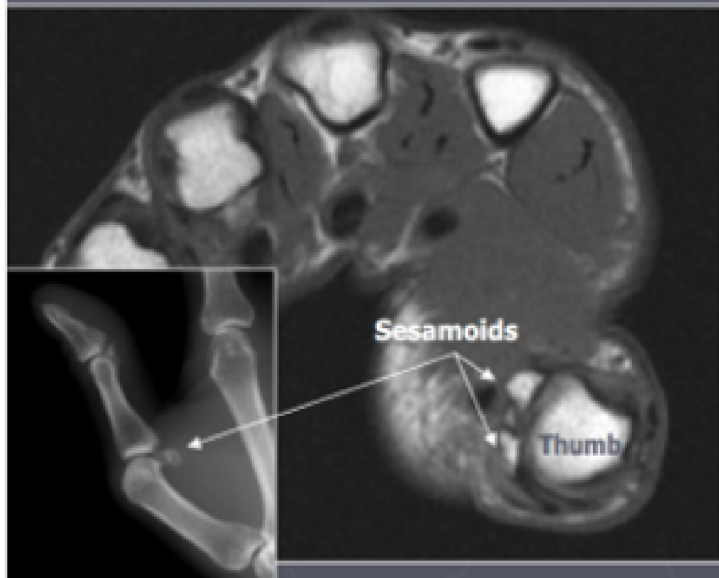
Important note: The planes should be relative to the **thumb metacarpal head** and **NOT** to the field of view.

PLANE	SEQUENCE	TR	TE	SLT/SP	FOV	NOTES
Coronal	PD FSE	>1500	30-50	3 / 0.3	10	
Coronal	T2 FSE FAT SAT	2000-6000	50-70	3/0.3	10	
Sagittal	FSE STIR	>1500	20-40	3/0.3	10-14	
Axial	T1 SE	400-800	minimal	3/0.3	10	
Axial	T2 FSE FAT SAT	2000-6000	50-70	3/0.3	10	



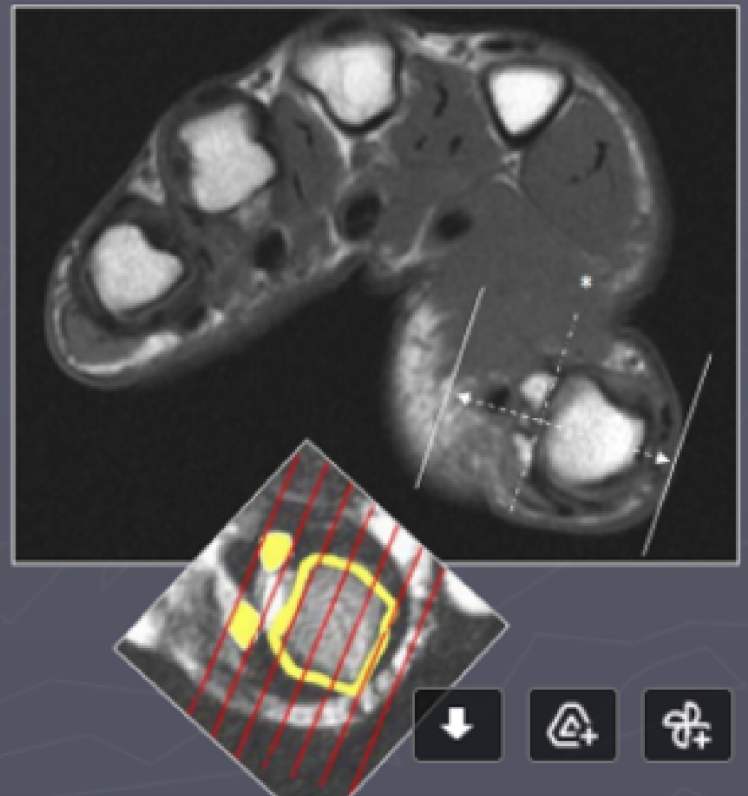
Important note: The planes should be relative to the **thumb metacarpal head** and **NOT** to the field of view.

Relevant Anatomy

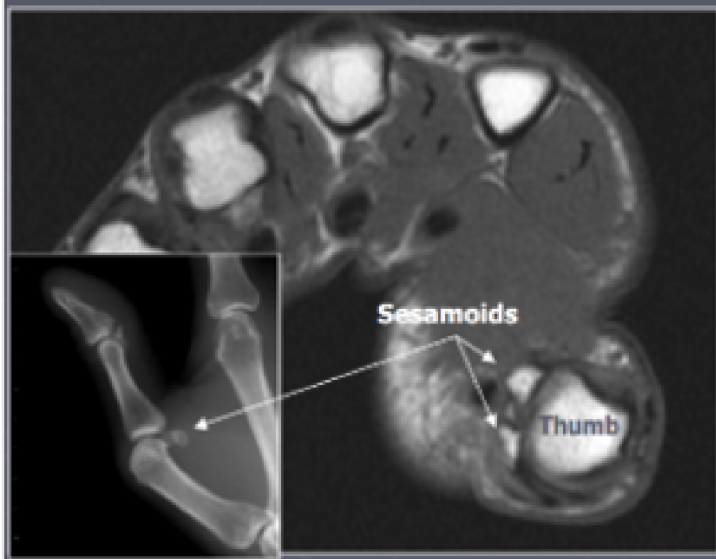


Coronal Imaging Plane

*Prescribe plane with line bisecting sesamoid bones. Scan through entire thumb.



Relevant Anatomy



Sagittal Imaging Plane

*Prescribe plane perpendicular to coronal imaging plane (©). Scan through entire thumb.

