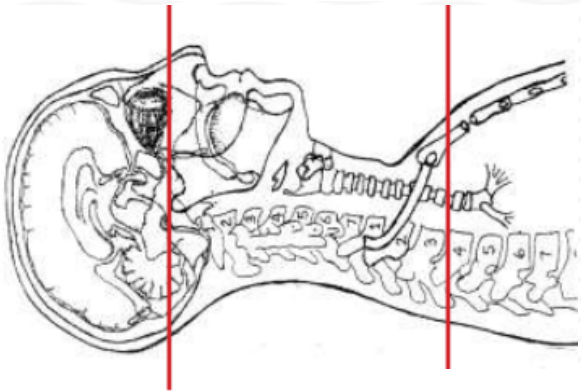
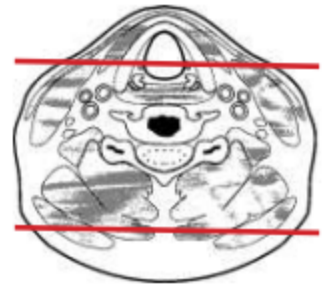
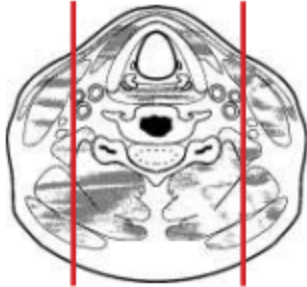
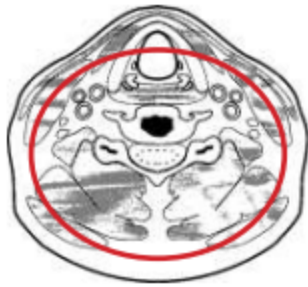CT CERVICAL SPINE WITH IV CONTRAST - POST MYELOGRAM



Patient position	Supine, IOML perpendicular to table (have patient tuck chin to chest) see image top left
Contrast	ADMINISTERED DURING MYELOGRAM
Injection rate	NONE
Respiration	Breath hold
Scan parameters	Sella turcica to T3. Use small SFOV



PLANE	ALGORITHM	THICKNESS	DFOV	
Axial + C	Bone	2.5 mm	approx 180 mm	
Axial + C	Soft tissue	2.5 mm		
Coronal & Sagittal + C	Bone	2.5 mm		Reformats
Coronal & Sagittal + C	Soft tissue	2.5 mm		Reformats

NOTES:

- LMP on pts of child-bearing age
- Shield children when possible
- Follow GFR and metformin protocol for contrast studies

Any deviation from protocol MUST be Radiologist approved. Rad Director will be notified if this occurs without prior approval.