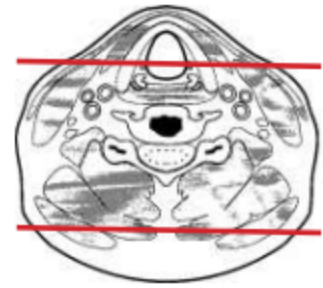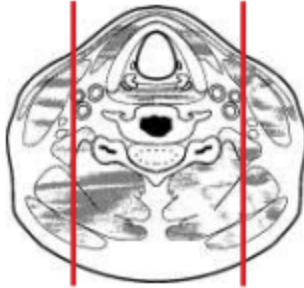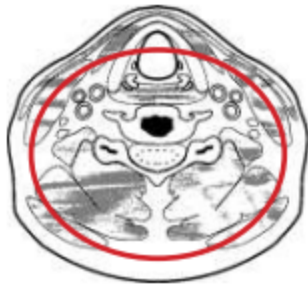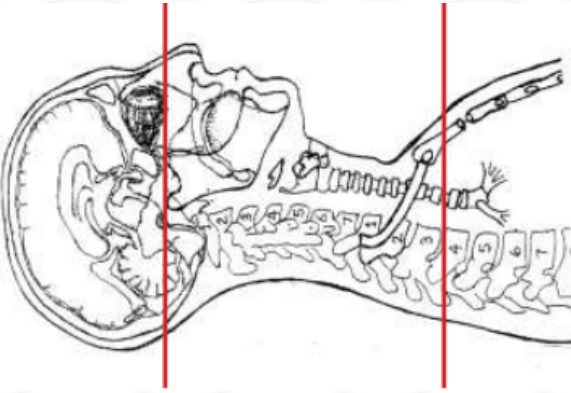


CT CERVICAL SPINE WITHOUT IV CONTRAST

Indications	Trauma. **IF CT C- T- L spine ordered, do as separate scans and use appropriate FOV for each area of the spine.
Patient position	Supine, IOML perpendicular to table
Contrast	NONE
Injection rate	NONE
Respiration	Breath hold
Scan parameters	Sella turcica to T3. Use small SFOV



PLANE	ALGORITHM	THICKNESS	DFOV	
Axial	Bone	3.0 mm	approx 140 mm	
Axial	Soft tissue	3.0 mm		
Coronal & Sagittal	Bone	3.0 mm		Reformats

NOTES:

- LMP on pts of child-bearing age
- Shield children when possible
- Follow GFR and metformin protocol for contrast studies

Any deviation from protocol MUST be Radiologist approved. Rad Director will be notified if this occurs without prior approval.