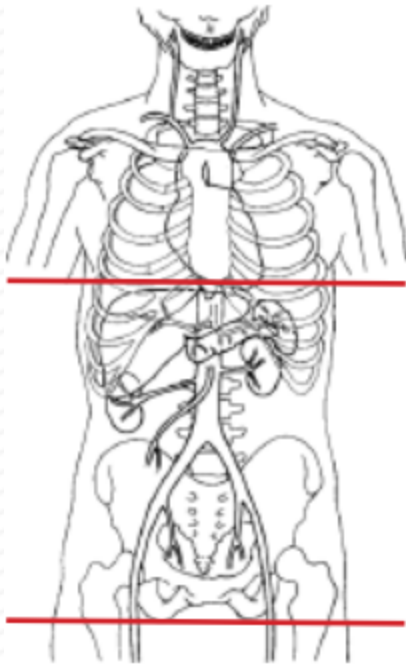


CT ENTEROGRAPHY



Indications	Crohn's disease, small bowel tumors, SB obstructions, malabsorption, adhesions, GI bleed w/ negative UGI
Contraindications	this exam is NOT for ischemia (need CT angiogram)
Patient Position	Supine
Contrast	VoLumen barium sulfate solution (E-Z-EM) IV: 120 mL Omni 350 (depends on pt weight)
Injection rate	IV= 3 mL/sec minimum 22 g
Respiration	Breath- hold
Scan Parameters	dome of diaphragm through ischial tuberosity
Oral contrast procedure	450 cc (2 bottles) = 60 minutes prior to CT. 450 cc (2 bottles) = 30 minutes prior to CT. 250 cc (approx half bottle of water) = 15 minutes after 4th bottle of VoLumen. Monitor patient carefully while consuming oral contrast.
Special Considerations	Before administering any IV contrast, perform a low mA single slice scan through mid-abdomen or topogram to check for adequate bowel distention. Make sure most of the VoLumen is NOT in the stomach before proceeding with exam.

PLANE	ALGORITHM	THICKNESS	DFOV	Reformat/Recon
Axial + C	Abdomen	2.5 mm	pt largest + 4 cm	Portovenous phase 60 - 75 sec delay
Coronal + C	Abdomen	2.5 mm/ 2.5 mm		X
Sagittal + C	Abdomen	2.5 mm/ 2.5 mm		X
Coronal + C	Abdomen	8.0 mm/ 5.0 mm		MIP