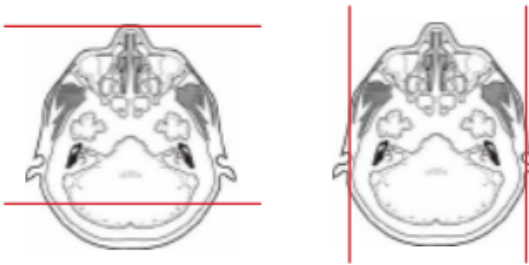
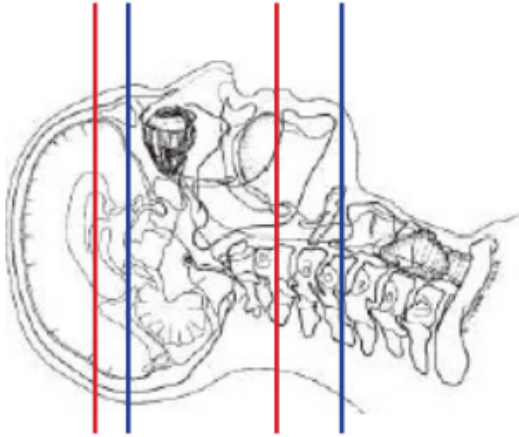


CT SINUS / FACIAL BONES WITH IV CONTRAST



Indications	Clivus lesions , craniopharygioma , exophthalmos , inflammatory disease of the orbit , invasive fungal sinusitis , inverting papilloma , mass of cavernous sinus , ocular masses , optic nerve and more posterior visual pathways , optic nerve glioma , orbital masses , orbital varix , retinoblastoma follow-up study , vascular lesions of the cavernous sinus , visual loss
Patient position	Supine, IOML perpendicular to table
Contrast	Yes
Injection rate	90 sec delay
Respiration	Breath hold
Scan parameters	SINUS: Above frontal sinus through hard palate. Use small SFOV
	FACIAL BONES: Just above orbits through bottom of mandible. Use small SFOV

PLANE	ALGORITHM	THICKNESS	DFOV	
Axial	Soft tissue	2.0 mm	170- 190 mm	
Axial, Sagittal, Coronal	Bone	2.0 mm		
If contrast needed				Approximately 90 sec delay
Axial + C	Bone	2.0 mm x 2.0 mm		
Axial, Sagittal & Coronal + C	Soft tissue	2.0 mm x 2.0 mm		
Coronal & Sagittal + C	Bone	2.0 mm x 2.0 mm		

NOTES:

- LMP on pts of child-bearing age
- Shield children when possible
- Follow GFR and metformin protocol for contrast studies

Any deviation from protocol MUST be Radiologist approved. Rad Director will be notified if this occurs without prior approval.