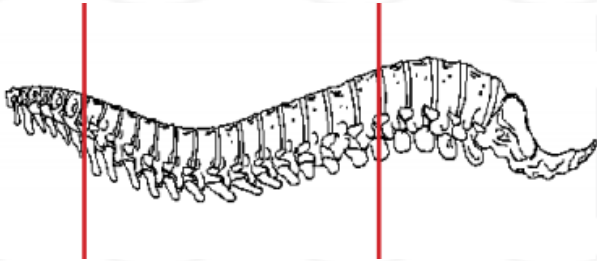
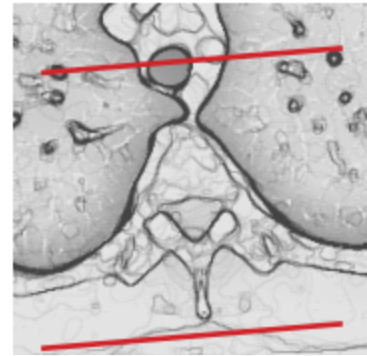
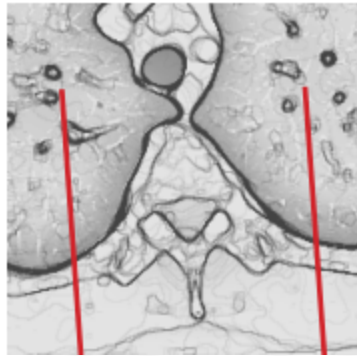
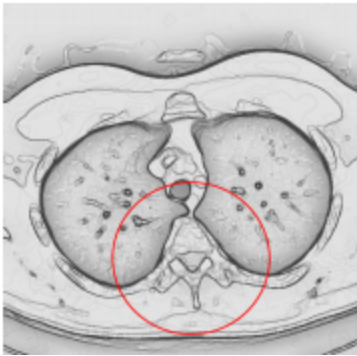


CT THORACIC SPINE WITH IV CONTRAST



Indications	CT T spine with contrast has limited applications primarily for patients where MRI is contraindicated or prior hardware placement. All other indications should be discussed with Radiologist and/or ordering physician as to why MRI would not be more optimal exam for evaluation of malignancy, infection, or disc disease.
Patient position	Supine
Contrast	IV = 100 mL
Injection rate	1.0 mL/sec with 90 sec delay
Respiration	Breath- hold
Scan parameters	C7 through L1. Use small SFOV



PLANE	ALGORITHM	THICKNESS	DFOV	
Axial + C	Bone	3.0 mm	approx 180 mm	
Axial + C	Soft tissue	3.0 mm		
Coronal & Sagittal + C	Bone	3.0 mm		Reformats

NOTES:

- LMP on pts of child-bearing age
- Shield children when possible
- Follow GFR and metformin protocol for contrast studies

Any deviation from protocol MUST be Radiologist approved. Rad Director will be notified if this occurs without prior approval.