

MRA HEAD WITHOUT and NECK WITH CONTRAST

Indications	Intracranial arterial stenosis, occlusion, abnormality
IV site	IV site in RIGHT arm
Localizer	3 plane scout
Notes	Precontrast MRA necessary before post contrast performed

PLANE	SEQUENCE	FAT SAT	SLT/SP	FOV	NOTES
Axial - head	T1		5 / 1.5	24 cm	entire brain to vertex
Axial - neck	T1	Y	2 - 5 mm	20 cm	thyroid gland to skull base
Axial - head	3D TOF		<u>< 1.5 or VOI</u>	20 cm	upper C-1 through upper 3rd ventricle. use 2 slabs if necessary
Axial - neck	2D and/or 3D TOF		<u>< 1.5 or VOI</u>	24 cm	cover from thoracic outlet to skull base
Axial neck + C	3D TOF		VOI	24 cm	minimum coverage from aortic arch to floor of sella. subclavian arteries 2 cm distal to the vertebral arteries.

****Do vendor appropriate timing sequence prior to CE-MRA**

Interval ≤ 0.75 on recons of neck

Send source images

Make sure MIP 'slices' are thin minimum
18 projections, 10 degree angle
Name each MIP

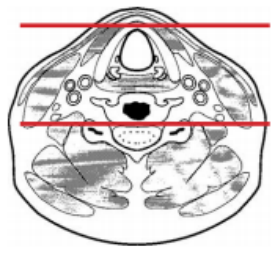
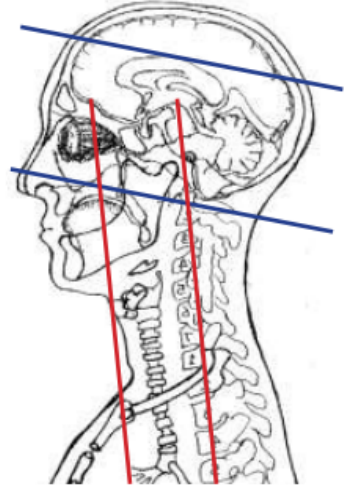
Post processing Neck

- MIP right half of neck in R to L rotation
- MIP Left half of neck in R to L rotation
- MIP entire neck in R to L rotation
- MPR in sagittal and coronal plane. Send source images

Post processing Head

MIP in R to L rotation and cranio-caudal "tumble" rotation

1. Right ICA, A1-2, M1-2
2. Left ICA A1-2, M1-2
3. Vertebrobasilar, PICA, and P1 & P2 posterior cerebral arteries



Any deviation from protocol MUST be Radiologist approved. Rad Director will be notified if this occurs without prior approval.