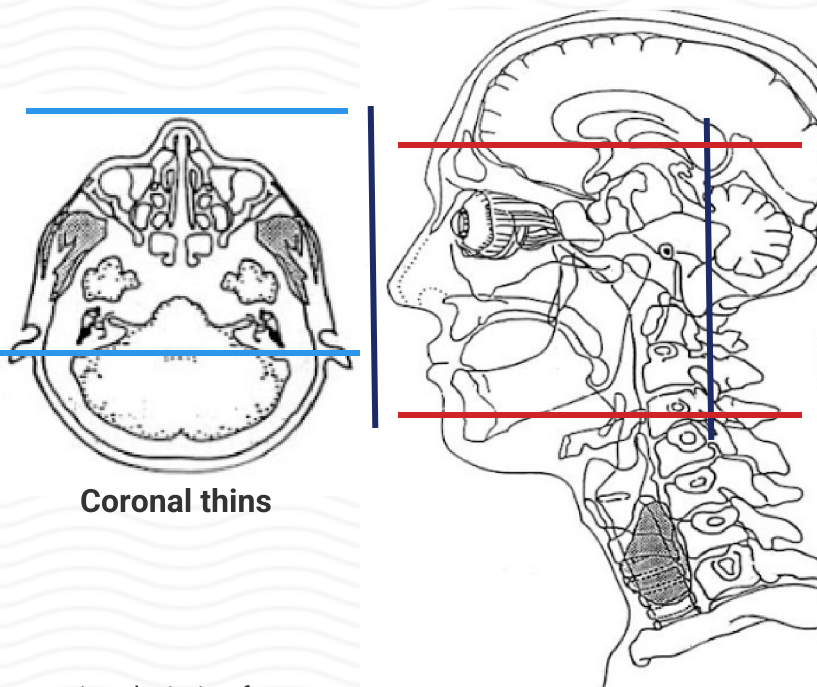


MRI FACE / SINUS WITHOUT & WITH CONTRAST

Indications	Sinus mass, face mass, tongue mass, infection
Localizer	3 plane scout
FOV	Use smallest FOV possible to include sinuses / ROI
Notes	Typical scan includes hyoid to supraorbital rim (axial) and fourth ventricle to nose (coronal)
	If ordered as a sinus MR, scan from entire maxilla through frontal sinuses
	**For skin cancer patients, include the entire nose.

PLANE	SEQUENCE	FAT SAT	MODE	SLT/SP	FOV	NOTES
Sagittal	T1			3-4 / 1	Small FOV	of face
Axial	T1			3-4 / 1	Small FOV	Parallel to hard palate / along Reid's baseline
Axial	T1	Y		3-4 / 1	Small FOV	Parallel to hard palate / along Reid's baseline
Axial	T2	Y		3-4 / 1	Small FOV	Parallel to hard palate / along Reid's baseline
Coronal	T1			3-4 / 1	Small FOV	Perpendicular to Reid's baseline
Coronal	T2	Y		3-4 / 1	Small FOV	Perpendicular to Reid's baseline
Coronal + C	T1	Y		3-4 / 1	Small FOV	Perpendicular to Reid's baseline
Axial + C	T1	Y		3-4 / 1	Small FOV	Parallel to hard palate / along Reid's baseline



Coronal thins