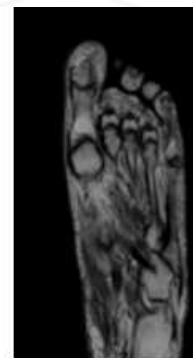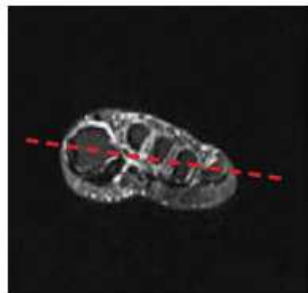

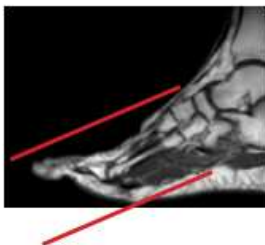
MRI FOREFOOT WITHOUT & WITH CONTRAST

Scan Range	Variable according to area of interest/ body part.
FOV	Fits to patient/ body part.
Position	Supine. Place in foot coil so metatarsals near center.
Localizer	3 plan scout localizer
NOTES	REMOVE SOCKS or STOCKINGS if any

PLANE	SEQUENCE	FAT SAT	MODE	SLT/SP	FOV	NOTES
Sagittal	T1				small FOV	
Axial	STIR				small FOV	
Axial	T1				small FOV	
Coronal	T2	Y			small FOV	
Sagittal	STIR				small FOV	
Axial	PD	Y			small FOV	
Coronal	T1	Y			small FOV	
Coronal + C	T1	Y			small FOV	
Sagittal + C	T1	Y			small FOV	



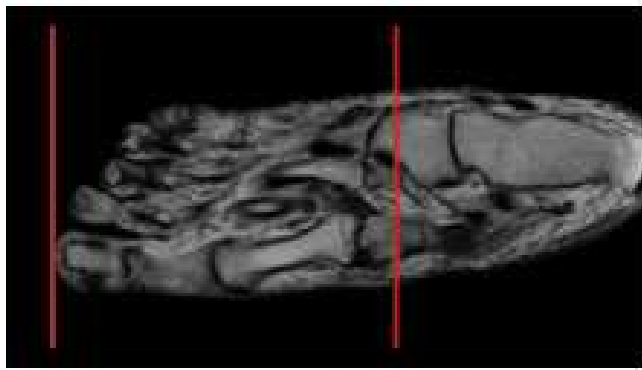
Prescribe AXIALS off sagittal and coronal scout

Example resulting image

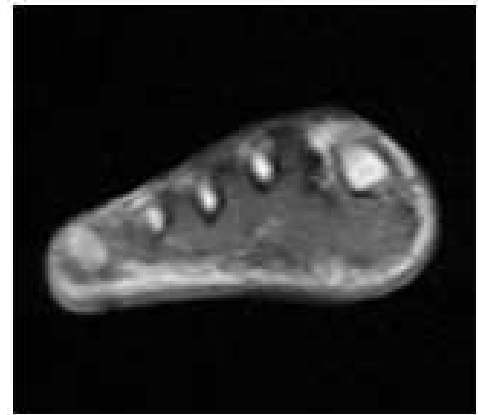AXIALS - LONG AXIS

- Use Sag LOC and angle parallel to the shaft of either the 2nd or 3rd metatarsals and at least cover the soft issues superior and inferior to the MTP joints
- Cover all of the toes and as far proximal as the field of view allows. THIS SHOULD BE TO THE METATARSAL BONES
- Look at the sagittal or longitudinal STIR images before you prescribe the transverse sections so that you can be sure you've covered all the pathology (bright signal on STIR = edema = pathology)

POSITIONING AND PLANES



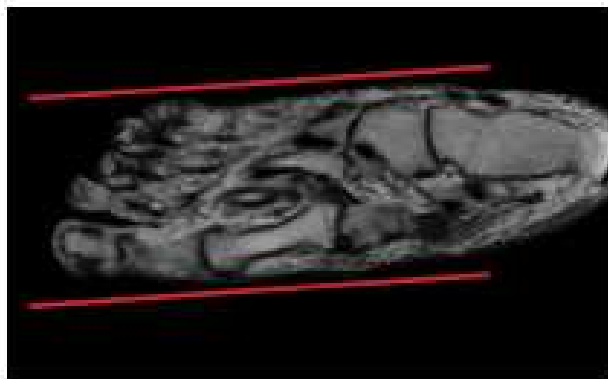
Prescribe CORONAL off axial plane



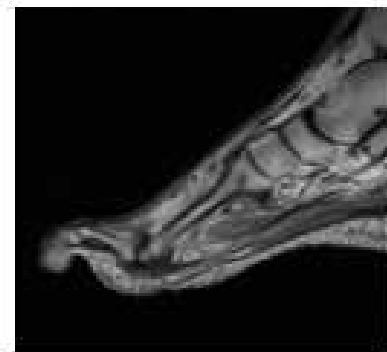Example resulting image

CORONAL - SHORT AXIS

- Perpendicular to Axial - long axis
- Angled perpendicular to 2nd metatarsal shaft
- Cover to end of toes



Prescribe SAGITTAL off axial plane



Example resulting image

SAGITTAL

- Parallel to 2nd metatarsal shaft on Axial sequence
- Cover from tips of the toes as far proximal as the FOV allows
- Cover from medial margin of 1st MTP joint as far lateral as the slices go (cover all of the MTP joints)