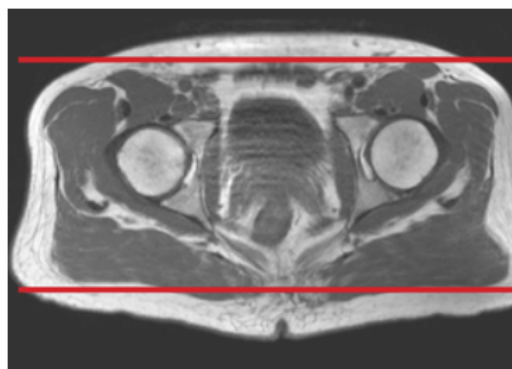
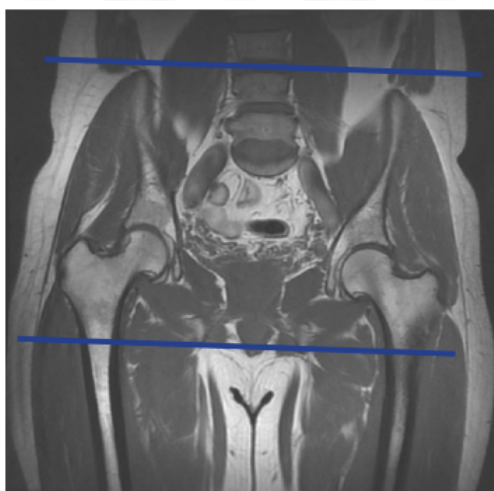


## MRI PELVIS BONY WITHOUT CONTRAST

|                  |   |
|------------------|---|
| Patient Position | Supine- feet internally rotated and patient made comfortable with sponges. Do not rotate if suspicion of femoral neck / hip fx. |
| FOV              | Fits to patient/ body part  |
| Localizer        | 3 plane scout localize  |



| PLANE    | SEQUENCE | FAT SAT | MODE | SLT/SP | FOV       | NOTES   |
|----------|----------|---------|------|--------|-----------|---|
| Coronal  | T1       |         |      |        | Full FOV  | Anterior to ilium to just past sacrum                 |
| Coronal  | STIR     |         |      |        | small FOV | Anterior to ilium to just past sacrum                 |
| Axial    | T1       | N       |      |        | small FOV | just above iliac crest to level of greater trochanter |
| Axial    | T2       | Y       |      |        | small FOV | just above iliac crest to level of greater trochanter |
| Sagittal | T2       | Y       |      |        | Full FOV  |   |