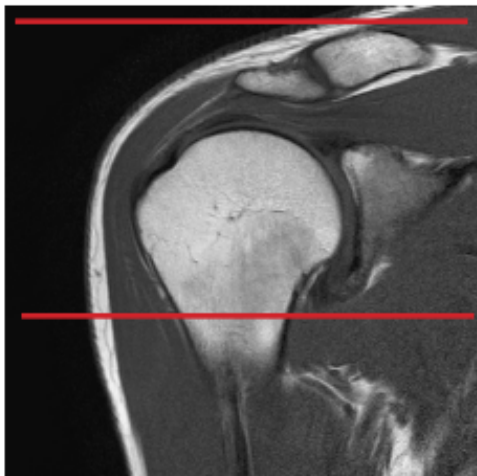


MRI SHOULDER ARTHROGRAM

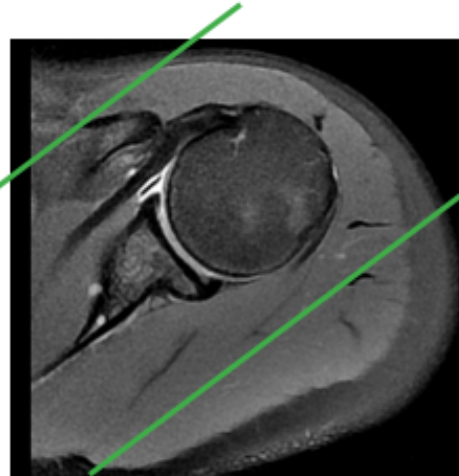
Scan Range	Variable according to area of interest/ body part.
FOV	Fits to patient/ body part.
Position	SUPINE- Arm in neutral position, palm up (tuck hand under hip for pt comfort and motion suppression). Center should as much as possible to center of table.
Localizer	3 plane scout localizer
Note	On all scans, be sure that all of the visualized contrast is covered within your scan range.

PLANE	SEQUENCE	FAT SAT	FOV	NOTES
Axial + C	T1	Y	12 - 18 cm	
Axial + C	PD	Y	12 - 20 cm	
Coronal oblique + C	T2	Y	12 - 20 cm	
Coronal oblique + C	T1	Y	12 - 20 cm	
Sagittal oblique + C	T1		12 - 20 cm	
Sagittal oblique + C	T1	Y	12 - 20 cm	



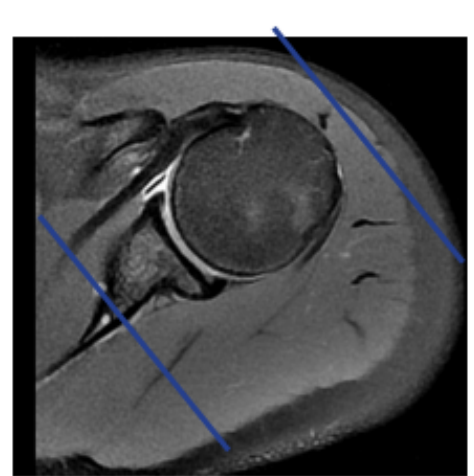
Axial imaging

- Use coronal LOC and plane is straight horizontal
- Cover from top of AC joint down and try to cover to the inferior portion of the glenohumeral joint axillary pouch



Coronal imaging

- Use axial sequence to orient the plane along the supraspinatus tendon
- Cover from anterior portion of coracoid process to 1 slice posterior to the humeral head



Sagittal imaging

- Parallel to axial sequence
- Angle approximately parallel to GH joint
- Cover from 1 slice out of humeral head to as far medial as slices allow