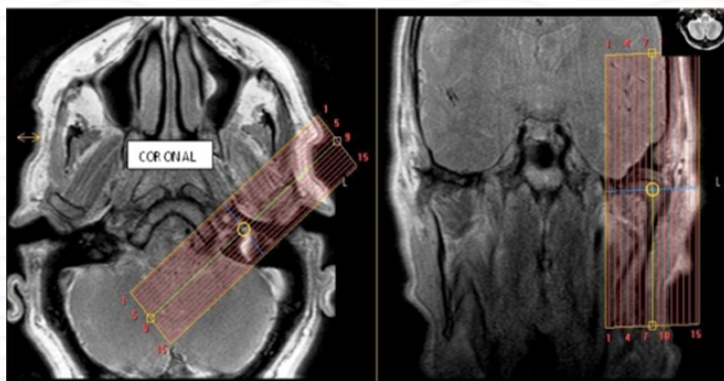


## MRI TMJ Without & with contrast

<b>Indications</b>	<b>inflammatory arthritis, etc</b>
<b>Notes</b>	<b>Always scan bilaterally. Scan right and left sides separately. LABEL sides correctly.</b>

PLANE	SEQUENCE	FAT SAT	MODE	SLT/SP	FOV	NOTES
Axial	T1			4/1	23 cm	Angle to Corpus - skill base to vertex
Axial	T1	Y		4/1		Angle to Corpus - skill base to vertex
Sagittal (right & left)	<b>PD closed</b>		TSE	2/0	12 cm	Perpendicular to long axis
Sagittal (right & left)	<b>T2 closed</b>		TSE	2/0	12 cm	Perpendicular to long axis
Coronal (right & left)	<b>T2 closed</b>		TSE	2/0	12 cm	Parallel to long axis
Sagittal (right & left)	<b>PD open</b>		TSE	2/0	12 cm	Perpendicular to long axis
Axial + C	T1	Y		4 /1	23 cm	

Coronal



Sagittal

