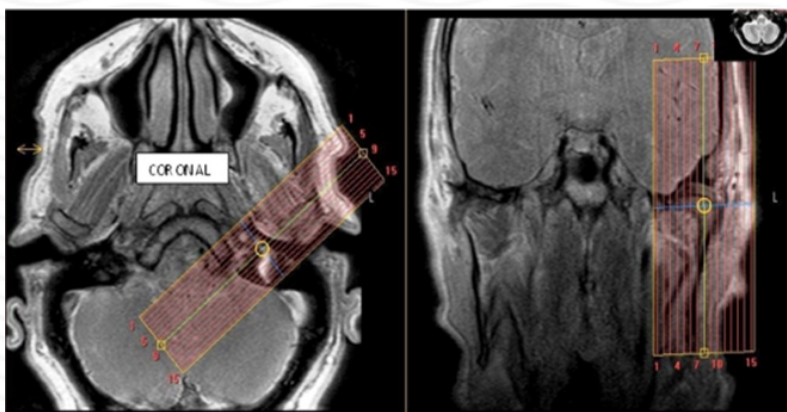


## MRI TMJ Without contrast

<b>Indications</b>	<b>clicking, pain, decreased ROM</b>
<b>Notes</b>	<b>Always scan bilaterally. Scan right and left sides separately. LABEL sides correctly.</b>

PLANE	SEQUENCE	FAT SAT	MODE	SLT/SP	FOV	NOTES
Axial	T1			4/1	23 cm	Angle to Corpus - skull base to vertex
Sagittal (right & left)	PD closed		TSE	2/0	12 cm	Perpendicular to long axis
Sagittal (right & left)	T2 closed		TSE	2/0	12 cm	Perpendicular to long axis
Coronal (right & left)	T2 closed		TSE	2/0	12 cm	Parallel to long axis
Sagittal (right & left)	PD open		TSE	2/0	12 cm	Perpendicular to long axis

Coronal



Sagittal

