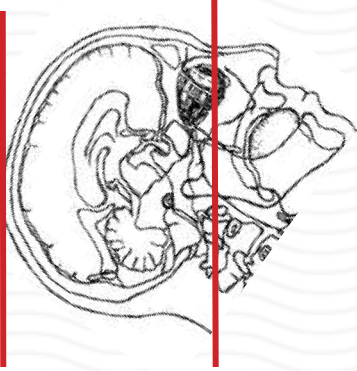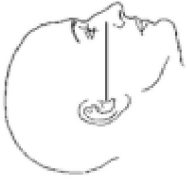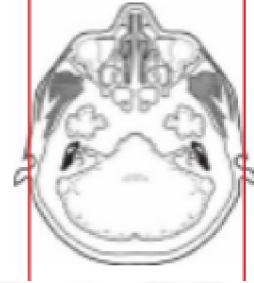
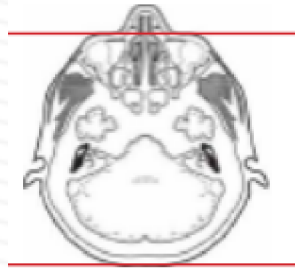


CT BRAIN WITHOUT



Patient position	Supine, IOML perpendicular to table (have patient tuck chin to chest) see image top left
Contrast	NONE
Injection rate	NONE
Respiration	Breath hold
Scan parameters	Base of skull to vertex. Use head SFOV
NOTE:	Pediatric patients (ages 0-3) for trauma cases and workup of craniosynostosis require 3D recons in BONE.



PLANE	ALGORITHM	THICKNESS	DFOV	
Axial	Brain	5.0 mm	approx 220 mm	
Axial	Bone	5.0 mm		
Coronal & Sagittal	Brain	5.0 mm		Reformats
3D Recon	BONE			see note above

NOTES:

- LMP on pts of child-bearing age
- Shield children when possible
- Follow GFR and metformin protocol for contrast studies

Any deviation from protocol MUST be Radiologist approved. Rad Director will be notified if this occurs without prior approval.